



The anterolateral complex of the knee: results from the International ALC Consensus Group Meeting

Alan Getgood¹ · Charles Brown² · Timothy Lording³ · Andrew Amis⁴ · Steven Claes⁵ · Andrew Geeslin⁶ · Volker Musahl⁷ on behalf of ALC Consensus Group

Received: 27 May 2018 / Accepted: 18 July 2018 / Published online: 25 July 2018
© European Society of Sports Traumatology, Knee Surgery, Arthroscopy (ESSKA) 2018

Abstract

The structure and function of the anterolateral complex (ALC) of the knee has created much controversy since the ‘re-discovery’ of the anterolateral ligament (ALL) and its proposed role in aiding control of anterolateral rotatory laxity in the anterior cruciate ligament (ACL) injured knee. A group of surgeons and researchers prominent in the field gathered to produce consensus as to the anatomy and biomechanical properties of the ALC. The evidence for and against utilisation of ALC reconstruction was also discussed, generating a number of consensus statements by following a modified Delphi process. Key points include that the ALC consists of the superficial and deep aspects of the iliotibial tract with its Kaplan fibre attachments on the distal femur, along with the ALL, a capsular structure within the anterolateral capsule. A number of structures attach to the area of the Segond fracture including the capsule-osseous layer of the iliotibial band, the ALL and the anterior arm of the short head of biceps, and hence it is not clear which is responsible for this lesion. The ALC functions to provide anterolateral rotatory stability as a secondary stabiliser to the ACL. Whilst biomechanical studies have shown that these structures play an important role in controlling stability at the time of ACL reconstruction, the optimal surgical procedure has not yet been defined clinically. Concern remains that these procedures may cause constraint of motion, yet no clinical studies have demonstrated an increased risk of osteoarthritis development. Furthermore, clinical evidence is currently lacking to support clear indications for lateral extra-articular procedures as an augmentation to ACL reconstruction. The resulting statements and scientific rationale aim to inform readers on the most current thinking and identify areas of needed basic science and clinical research to help improve patient outcomes following ACL injury and subsequent reconstruction. *Level of evidence V.*

Keywords Anterolateral complex · Kaplan fibres · Iliotibial band · Anterolateral ligament · Anterior cruciate ligament

Introduction

Since the 2013 publication by Claes et al. regarding the anatomy of the anterolateral ligament (ALL) [7], there has been a great deal of controversy surrounding the presence of the ALL and its potential role in the control of anterolateral rotatory laxity of the knee following anterior cruciate ligament (ACL)

injury. Numerous anatomical and biomechanical studies have followed, with conflicting results. While some studies have been promoting the importance of the ALL [4, 7, 12, 27], others have been refuting it [15, 44, 57]. Journal editorials have been written, some favouring [33] and others questioning the significance of the ALL [37], and orthopaedic meetings are filled with varying opinions and interpretations of the published data. Clinical studies have been published, with members of the orthopaedic community developing new ways to address the ‘rediscovered ligament’, whilst others have focused on the anterolateral soft tissues, including the iliotibial band and its deep capsule-osseous layer, as a complex that may or may not need to be addressed in the face of ACL injury [18].

With such controversy comes the need for clarity of thought, and a focus on those specific areas where evidence is lacking. With good resources at hand, evidence should

The members of the ALC Consensus Group are listed in Acknowledgements.

Electronic supplementary material The online version of this article (<https://doi.org/10.1007/s00167-018-5072-6>) contains supplementary material, which is available to authorized users.

✉ Alan Getgood
alan.getgood@uwo.ca

Extended author information available on the last page of the article

be utilised to guide treatment paradigms; and where such evidence is lacking, the need for studies investigating specific research questions should be identified. To this end, an international consensus group was convened, with the task of producing a position statement on the current evidence in terms of the anatomy and function of the anterolateral complex (ALC), and the assessment and treatment of ALC injuries in association with an ACL injury.

Thirty-six international researchers and clinicians in the field were invited to join a meeting to discuss the below points pertaining to the ALC and anterolateral rotatory laxity. The group met in London, UK, in October 2017 with the specific aims of:

1. Developing a consensus in terms of the anatomical terminology utilised for structures within the ALC.
2. Producing position statements as to the kinematic role of key structures in the knee, pertaining specifically to anterolateral rotatory laxity and ACL deficiency.
3. Providing clinical guidance on when to utilise an anterolateral procedure in the ACL-deficient knee.

Materials and methods

Thirty-six researchers and clinicians were initially contacted via email and asked to complete an online survey compiled by the Chairs of the meeting (AG and CB). The questions posed and collated responses may be found in the supplementary material.

Based on the responses of 33 participants, 22 statements were generated pertaining to the 3 main aims of the meeting. A modified Delphi consensus discussion was then held during a 1-and-a-half-day meeting in London UK, attended in person by 26 individuals, with 3 individuals providing prerecorded presentations and a further 2 calling in via teleconference. Each structured session included a summary of the published literature, as well as time in the cadaveric laboratory for dissections of the ALC and associated structures and demonstration of reconstructive techniques. Following each structured session, a consensus discussion was held, moderated by the two chairs of the meeting (AG and CB). Each statement generated from the results of the survey was discussed and revised, until an acceptable level of consensus was achieved. A majority of 80% were determined a priori as being a satisfactory level of consensus. Opposing views were documented. Statements that did not reach the required majority, or those that were felt to not be relevant were discarded from the final paper.

Consensus statements and discussion

Following discussion of the available evidence, 13 statements were accepted and are presented below. These are accompanied by a summary of the pertinent evidence and rationale supporting each statement.

Anatomy

1. The ALL is a structure within the anterolateral complex.
2. The structures of the anterolateral complex, from superficial to deep, are:
 - Superficial IT band and iliopatellar band
 - Deep IT band incorporating
 - Kaplan fibre system
 - Supracondylar attachments
 - Proxima
 - Dista
 - Retrograde (Condylar) attachment continuous with the Capsulo-osseous layer of the IT band
 - ALL and capsule
3. The ALL is a capsular structure within Seebacher Layer 3 [46] of the anterolateral capsule of the knee.
4. The ALL has variable gross morphology between individuals in terms of size and thickness.
5. The ALL predominantly attaches posterior and proximal to the lateral femoral epicondyle and the origin of the LCL, runs superficial to the LCL and attaches on the tibia midway between the anterior border of the fibular head and the posterior border of Gerdy's Tubercle.
6. There is an attachment of the ALL to the lateral meniscus.

Numerous historical studies have investigated the structures on the anterolateral side of the knee, from Segond's description of the eponymous fracture of the anterolateral tibia [47], to Kaplan's original work in 1958 describing the layers and attachments of the iliotibial band (ITB) to the femur [26] and then on to the paper by Terry et al., breaking down the lateral fascia lata into its component parts [55]. It was Terry et al., in fact, who first described the iliotibial tract as the 'true anterolateral ligament of the knee'. Further work by Lobenhoffer et al. in 1987 documented the existence of a retrograde fibre tract, providing a static stabiliser of the lateral side of the knee via its connection from the deep fibres of the IT tract to the lateral tibial plateau [31]. In this article, they commented that this was the same structure that Müller had previously called the 'lig. Femoro-Tibiale laterale anterius' [35].

Descriptions of the anterolateral complex anatomy are confused by overlapping nomenclature. Vieira et al. are often attributed to being the first to describe the ALL [58], although this was the same name that Terry et al. used to describe the capsule-osseous layer of the iliotibial tract. Vincent et al. further described a structure that was more anterior to the lateral collateral ligament (LCL) [59], with a later paper suggesting that the new ALL was in fact the same structure that had previously been described by Hughston, namely the mid third capsular ligament [4]. Following the initial description by Claes et al. [7], two later studies [12, 27] have provided the most distinct descriptions of this structure that we now refer to as the ALL. Histologically, this structure has been characterised by dense and well-organised connective tissue collagen bundles consistent with ligamentous tissue [16]. Furthermore, it has been demonstrated that the ALL has significantly different biomechanical properties to adjacent capsule and similar properties to other capsular ligaments such as the inferior glenohumeral ligament [49].

Seebacher et al. described Layer 3 of the anterolateral capsule as splitting into a superficial and deep lamina anterior to the LCL, and enveloping it [46]. Based on this information, the group concluded that the ALL is a structure within Layer 3 of the anterolateral capsule, and that the superficial lamina is the ALL with the deep lamina being the true capsule of the knee at this level.

The present lack of consensus in terms of the nomenclature used to describe the various structures of the ALC stems from a number of issues, including:

- lack of clear photographs and corresponding diagrams in historical papers;

- description of anatomy on both embalmed and fresh specimens;
- differences in dissection technique that may introduce 'dissection artefact', i.e., the inadvertent creation of anatomic structures due to the dissection technique utilised.

Following demonstration of a number of dissection protocols [4, 9, 29], the group was able to identify and describe the key structures of the anterolateral complex, as illustrated in the attached figures (Figs. 1, 2, 3, 4, 5, 6, 7).

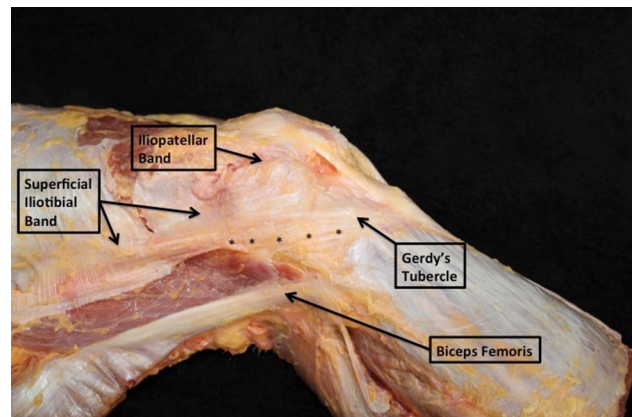


Fig. 1 Lateral structures of the right knee showing the superficial IT band, iliopatellar band and the attachment to Gerdy's tubercle. The line of asterisks represents the deep IT band corresponding to the capsulo-osseous layer

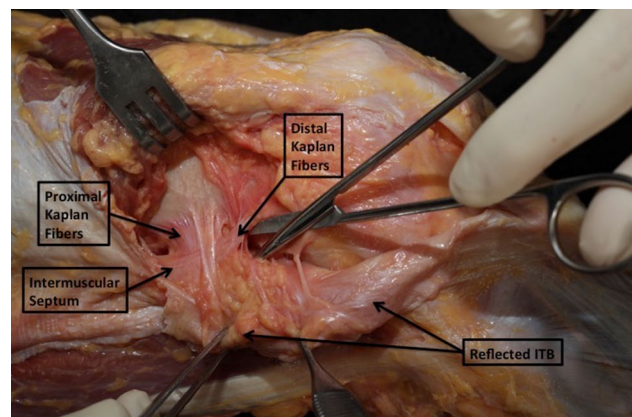


Fig. 2 The superficial ITB is reflected posteriorly, demonstrating the Kaplan fibre system. The proximal and distal (supracondylar) fibres are shown, continuing distally from the intermuscular septum

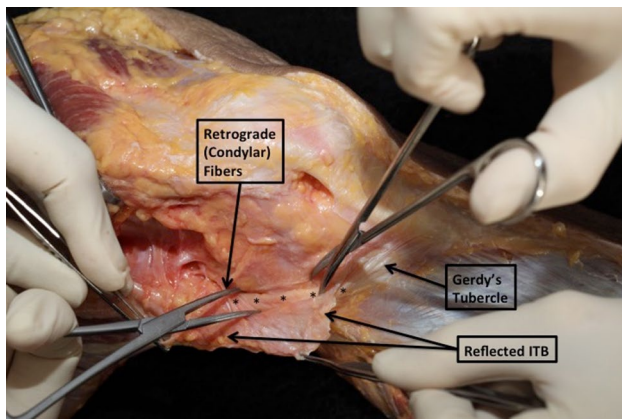


Fig. 3 The retrograde (condylar) Kaplan fibres are shown to be continuous with the capsulo-osseous layer of the ITB, as marked by the line of asterisks attaching distally to Gerdy's tubercle

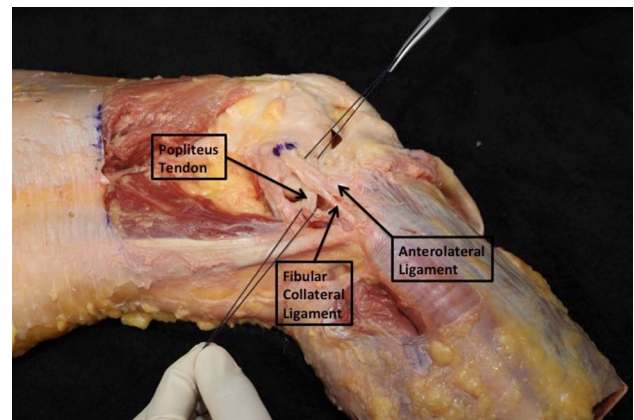


Fig. 6 The close relationship of the ALL, FCL and popliteus tendon is demonstrated

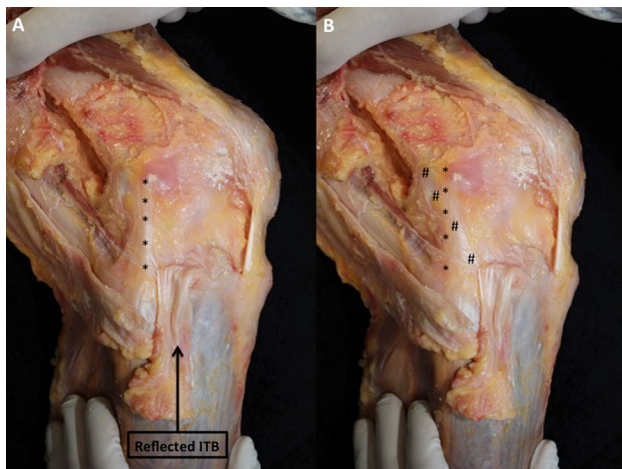


Fig. 4 a The FCL (asterisk) is shown with the knee at 90°, neutral tibial rotation; **b** an internal tibial rotation torque is applied to the tibia demonstrating the ALL (hash) tensioned across the FCL, running from posterior and proximal to the lateral femoral epicondyle to a position midway between the fibular head and Gerdy's tubercle

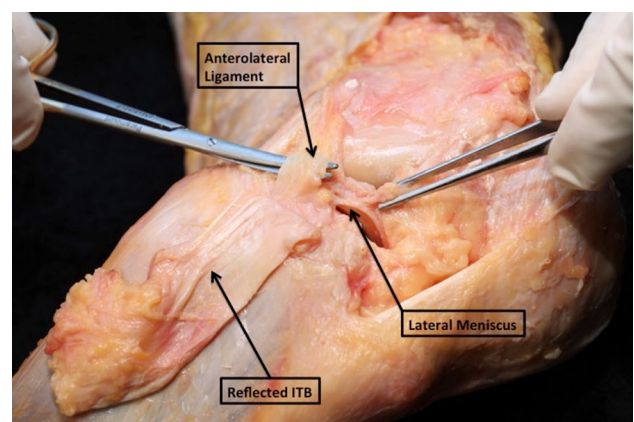


Fig. 7 The relationship of the ALL and lateral meniscus is demonstrated, with the scissor demonstrating the course of the lateral inferior geniculate artery. Meniscofemoral and meniscotibial attachments of the ALL can be observed

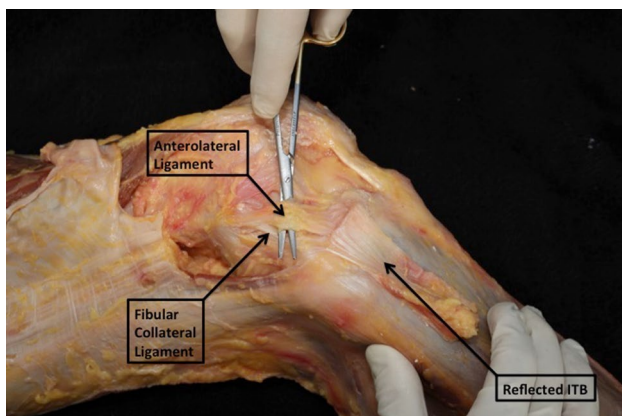


Fig. 5 The ALL is dissected free from the FCL, shown to be within Layer 3 of Seebacher's layers of the lateral retinaculum

Second fracture

7. Multiple structures (ALL, deep ITB and biceps aponeurosis) attach in the region of the Second fracture and it remains unclear which may be responsible for this lesion

In regard to the Second fracture, much debate ensued in regard to the cause of this bony avulsion. Segond originally described a ‘fibrous pearly band’ attached to the bony avulsion that we now call the Segond fracture, which is pathognomonic of an ACL injury [47]. Whilst there is little objective evidence as to the cause of this injury pattern, several authors have demonstrated that the previous literature has probably underestimated the incidence of this injury pattern, with two studies observing that the incidence on ultrasound (30–50%) is higher than visualised with either plain radiographs or MRI [5, 30]. More recent studies suggest that it is not only the ALL that attaches in this region [6], but also the capsulo-osseous layer of the IT tract as well as an expansion of the short head of biceps fascia [1].

Biomechanics of the anterolateral structures

6-degree-of-freedom robot. Two studies incorporating navigation demonstrated increased internal rotation laxity during a dynamic pivot shift test following an ACL/ITB-deficient [51] and ACL/ALL-deficient [34] setting.

A further study, using a 6-degree-of-freedom robot, examined the effect of ALL sectioning, as well as division of the superficial and deeper layers of the iliotibial tract [28]. The ALL was found to have only a minor role in controlling internal rotation in the ACL-deficient knee. The IT tract, in particular the deep and capsulo-osseous layers, made a greater contribution to internal rotation control at larger flexion angles, with the ACL having its greatest contribution closer to extension.

Conversely, the anterolateral capsule was examined during anterior translation and internal rotation by means of optical tracking analysis and strain mapping [15]. These researchers observed the anterolateral capsule to behave more like a fibrous sheet rather than a distinct ligamentous structure, disputing the existence of a discrete ALL.

8. The primary soft tissue stabiliser of coupled anterior translation and internal rotation near extension is the ACL. Secondary passive stabilisers include:
- The ITB including the Kaplan fibre system
 - The lateral meniscus
 - The ALL and the anterolateral capsule
9. The ALL is an anisometric structure

A number of important cadaveric biomechanical studies have been published investigating the kinematics of the knee following sectioning of the ACL and the anterolateral structures. Sectioning of the ALL was observed to result in a statistically significant increase in anterior translation and internal rotation after the ACL was sectioned during an early phase pivot shift [54]. Similar findings were also published in another study [43], clearly showing an increase in internal rotation following ALL sectioning using a

Furthermore, a serial sectioning study showed that the ALL only engaged in load sharing beyond the physiological limits of the ACL [57]. As such it was concluded that the ALL was a secondary stabiliser to anterolateral translation only after loss of the ACL, rather than a co-stabiliser.

Similar conclusions were made by Noyes’s group, who further examined the role of the ALC structures during a simulated pivot shift [21]. This was the first study to utilise a combination of anterior translation, valgus and internal

rotation. During this study, they demonstrated that an isolated ALL sectioning in the ACL intact knee resulted in no increase in anterior tibiofemoral compartment translation, concluding that the ALL does not function as a primary restraint to the pivot shift [21]. In a further study, the same group observed that sectioning of the ALL and the ITB in ACL-deficient knees converted 71% of the specimens to a grade 3 pivot shift as measured by composite tibiofemoral translations and rotations [39]. In addition, another study demonstrated that when a combined ACL and anterolateral injury exists, isolated ACL reconstruction fails to restore normal knee kinematics. Specifically, it was demonstrated that only combined ACL and lateral extra-articular procedures (ALL reconstruction or lateral tenodesis) were able to restore normal kinematics in this scenario [24].

The lateral meniscus also plays a role in the control of anterolateral rotation. Two studies [32, 48] have both shown increased lateral compartment anterior translation and internal rotation in the setting of lateral meniscus posterior root tears. The role of the ALL as a peripheral anchor of the lateral meniscus has been questioned, with an observation that the infra-meniscal ALL fibres were significantly stiffer and stronger than the supra-meniscal fibres [8]. The clinical significance of the infra-meniscal fibres is yet to be determined.

Biomechanics of lateral extra-articular procedures

knee of both a Lemaire-type lateral extra-articular tenodesis (LET) compared with an ALL reconstruction as described by Claes et al. was studied [54]. The ALL reconstruction had little effect on controlling rotation or translation; however, we now know that the anatomical description that formed the basis of this reconstruction was incorrect as the femoral graft position was anterior and distal to the lateral epicondyle, not posterior and proximal. The LET produced a composite reduction of rotation and translation with the latter reaching statistical significance.

The length change patterns of ALC reconstructions based upon graft attachment site was also investigated [29]. In this study, the most isometric position was a proximal and posterior attachment on the femur, attached distally to Gerdy's tubercle and with the graft passed deep to LCL. They, therefore concluded that a LET would be the most efficient form of reconstruction if passed deep to the LCL.

In regard to the ALL, it has been demonstrated that a femoral attachment posterior and proximal to the origin of the LCL resulted in minimal length change during the flexion cycle [12]. Conversely, if using the femoral attachment described by Claes et al. [7], a number of authors have shown that the ALL lengthens with flexion, and as such would cause the ALL to tighten in higher degrees of flexion [3, 29, 62]. From these studies, it is clear that if an ALL reconstruction is to be of benefit in controlling the pivot shift, then an attachment posterior and proximal to the LCL and hence posterior to the centre of rotation of the knee, should be chosen, so that the ALL graft is tight near knee extension.

ALL reconstruction and LET have now been compared in ACL-reconstructed knees. One study observed that an

10. Time zero biomechanical studies show lateral extra-articular procedures used as an augmentation to ACL reconstruction have the potential to over-constrain normal motion of the lateral compartment compared to the intact knee. The clinical significance of this is as yet unknown.
11. Causes of over-constraint of lateral extra-articular procedures may include:
 - Fixation of the graft with the tibia in external rotation
 - Over-tensioning of the graft
12. Despite concerns often being raised, to date the group is not aware of any clinical evidence that lateral extra-articular procedures used as an augmentation to ACL reconstruction lead to accelerated progression of OA

A number of studies have now examined the biomechanics of ALC reconstruction, most of them acknowledging the difficulties with extrapolating artificially created injury patterns and laboratory results to the clinical scenario. The effect on anterior translation and internal rotation in an ACL-deficient

LET graft tensioned at 20 N and passed deep to the LCL was effective at controlling rotation with minimal over-constraint of internal rotation [25].

Both a modified Lemaire tenodesis and a modified Macintosh tenodesis, with a graft path deep to the LCL, were found

to restore intact knee kinematics in combination with an anatomic ACL reconstruction. Furthermore, an ALL reconstruction based on previous anatomic descriptions was found to provide minimal effect on internal rotation of the knee.

In another study, the same authors demonstrated that by passing an LET graft deep to LCL, the graft could be tensioned at a number of different flexion angles with no detrimental effect [24]. The same study also demonstrated that the ALL reconstruction described by Sonnery-Cottet et al. only controlled knee laxity when their ALL reconstruction was tensioned in full extension [24]. A similar study observed that an ALL reconstruction using a single graft tensioned with 88 N caused significant over-constraint of internal rotation, no matter what angle of fixation was used [45]. The high graft tension in this study has been questioned and may explain the over-constraint observed, with later studies suggesting 20 N to be the optimal [25]. A further study by the same group compared their ALL reconstruction (based on the anatomy described by Kennedy et al. [27]) to the modified Lemaire technique, utilising varying knee flexion and graft tension parameters at fixation. In this study, they found that the Lemaire LET resulted in greater reduction in anterior translation and internal rotation during a simulated pivot shift manoeuvre compared to the ALL reconstruction; however, both reconstructions caused an element of over-constraint [14].

At time zero, in a knee with combined ACL and ALC injury, an anatomically placed bone-patellar tendon-bone (BTB) ACL reconstruction secured in 25° of knee flexion adequately controlled knee kinematics without the need for an additional ALL reconstruction during a simulated pivot shift [38]. However, a residual increase of 5°–7° of internal tibial rotation occurs with ALC injury at high flexion angles, which is not controlled by ACL reconstruction. The clinical significance of this was questioned as an indication for a concurrent LET procedure.

Similarly, the role of LET in both an isolated ACL injury and ACL plus ALC injury has been investigated [19]. These researchers concluded that the addition of an LET had no additional benefit to knee stability in the isolated ACL-deficient knee when an ACL reconstruction was performed. However, the LET was required in the combined injury to restore normal knee kinematics. The question raised by this

work is whether an isolated ACL injury is often seen, or if a concomitant ALC injury occurs at the time of ACL rupture. Based on a number of other studies, it is clear that in a knee demonstrating a high-grade laxity pattern, an isolated ACL injury is rarely seen. Instead, concomitant meniscus and lateral soft tissue injuries are often observed, which may further support the need for an anterolateral procedure in combination with an ACL reconstruction [36]. The prevalence of concomitant anterolateral structure lesions in acute ACL injuries have been reported to vary from 40 to 90% depending on the chosen method of detection [5, 13, 17].

At present, it is not possible to ascertain which reconstruction technique is superior to another, as the experimental setup and associated testing protocols differ between studies. If using an LET type procedure, it is recommended to pass the graft deep to the LCL prior to femoral fixation [24, 29]. Passing the graft deep to the LCL appears to provide a more optimal direction of action throughout the flexion cycle, as well as providing a more forgiving position of fixation, in terms of avoiding over-constraint, as the LCL attachment serves as a fulcrum. If instead performing a combined ACL and ALL reconstruction, the technique described by Sonnery-Cottet, tensioned in full extension, would appear to provide the most optimal ALL reconstruction kinematics [24].

Concerns relating to over-constraint of the lateral compartment remain an issue. Lateral compartment contact pressures following LET have been investigated [23]. It was demonstrated that a small increase in lateral compartment contact pressure was observed after LET. However, the increased pressure was found to be insignificant compared with the contact pressure seen in the lateral compartment during normal physiological loading [23]. The clinical importance of over-constraint of internal rotation is currently unknown, but to date there is no known evidence supporting lateral extra-articular procedures causing or accelerating the development of osteoarthritis [11].

Clinical evidence for augmentation of ACL reconstruction with lateral extra-articular procedures

13. Clinical evidence is currently lacking to support clear indications for lateral extra-articular procedures as an augmentation to ACL reconstruction. Appropriate indications may include:
 - Revision ACL
 - High-grade pivot shift
 - Generalised ligamentous laxity/Genu recurvatum
 - Young patients returning to pivoting activities

Lateral extra-articular tenodesis has a long clinical history. Having been the stand-alone procedure of choice to address anterolateral knee laxity in the first half of the twentieth Century by Strickler, Lemaire and later Macintosh, it soon became apparent that intra-articular ACL reconstruction would provide a better control of knee stability. Surgeons reported the results of their lateral reconstruction, which was developed to aid in the control of anterolateral rotatory stability, later to be added to intra-articular ACL reconstruction. Lemaire, Losee, Andrews, Ellison and later versions of the Macintosh to name but a few were reported in a variety of publications. Recent meta-analyses have shown that these combined procedures performed well at reducing rotatory laxity, but no differences in anterior translation nor patient-reported outcomes were observed [10, 20, 50].

Whilst remaining popular in Europe, the addition of an LET fell out of favour in North America following publications from O'Brien et al. [40] and Anderson et al. [2]. The former paper was a retrospective comparison of BTB ACL reconstruction with or without a lateral tenodesis in 80 patients. Whilst there were significant methodological limitations of this study, in particular its underpowered nature to elicit a difference in clinical outcome, the lack of differences in outcome and the concern of over-constraint in these patients led to the recommendation from an AOSSM consensus group to abandon the lateral-based procedures [41]. A commentary from Andrews in the American Journal of Sports Medicine following publication of the O'Brien paper suggested that whilst good results can be achieved with an isolated BTB ACL reconstruction, there are likely to be individuals who may still benefit from a lateral procedure. The latter paper of Anderson compared three surgical techniques, concluding that similar results could be found with either a hamstrings or patellar tendon autograft ACL reconstruction, with a lateral tenodesis offering very little benefit. Of note, they cautioned about the risk of over-constraint of internal rotation, and hence the concern for the development of OA, although this was not specifically studied.

With recent methodologically rigorous studies showing a high failure rate in young patients [60], there is likely room for improvement in ACL reconstruction methods. However, these failures cannot all be attributed to the technique itself, as there are many reasons for ACL reconstruction failure. These include poor neuromuscular rehabilitation, early return to sport and participation in high risk pivoting sports. However, at the time of surgery, there are still many areas where surgeons can influence outcome. Good surgical technique is paramount, including avoidance of the technical error of improper graft placement. Failure to address meniscal tears, concomitant soft tissue laxity patterns and issues of alignment may all contribute to a higher risk of ACL failure.

Systematic reviews with meta-analyses of comparative studies [10, 20, 50] have all demonstrated that the addition

of a lateral-based procedure to an ACL reconstruction improves rotational laxity control, but has no impact on anterior translation nor patient-reported outcomes. Importantly, no studies have demonstrated an increased risk of osteoarthritis with the addition of an LET. Zaffagnini et al. recently published the 20 year outcomes of an over-the-top hamstring ACL reconstruction with a lateral tenodesis [61]. There was no generation of lateral compartment or patellofemoral OA associated with the procedure. Similar results were found in a long-term follow-up of patients treated in Lyon [42]. A more recent meta-analysis did not find any evidence of OA in the knee in 11 years of follow-up, contrary to reports of isolated LET procedures which clearly showed an increased prevalence of OA when the ACL was not addressed concomitantly [11].

At present, there is no high-level evidence to guide clinicians as to when a lateral-based procedure should be added to an ACL reconstruction. Historic studies have tended to include 'all-comers', and were generally based upon small numbers of patients. Sub-group analyses in meta-analyses have, therefore, not been possible due to the significant heterogeneity of inclusion and exclusion criteria.

The more recent studies by Sonnery-Cottet et al. have demonstrated the potential benefit of adding an ALL graft to a hamstring tendon ACL reconstruction. In 2015, 2-year outcomes of 92 patients were reported demonstrating only a 1% re-rupture rate with only 7 patients having a grade 1 pivot shift [53]. This was followed in 2017 by a comparative cohort study of 502 young patients engaging in pivoting sports, and therefore exposed to a high risk of graft rupture, undergoing ACL reconstruction [52]. In the largest comparative series of any type of extra-articular reconstruction to date, the data have demonstrated significantly lower ACL graft rupture rates in the combined ACL and ALL group (4%) when compared to isolated patellar tendon (16%) and hamstrings tendon autograft (10%) groups, with a further study observing low complication rates [56].

In contrast, a recent study has shown minimal differences in the outcome following addition of an ALL graft to a standard hamstrings autograft ACL reconstruction [22]. However, this study utilised a non-anatomic ALL reconstruction technique (femoral insertion proximal and anterior to LCL, instead of posterior and proximal), which was underpowered and did not select out patients who would be at a higher risk of failure, such as young patients returning to pivoting sport or those with high-grade laxity.

Based on the current evidence, the consensus group was unable to make definitive recommendations as to when a lateral procedure should be added to an ACL reconstruction.

Conclusions

The 13 consensus statements generated from the ALC Consensus group are intended to provide some clarity of anatomical nomenclature and a better understanding of pertinent biomechanics associated with the ALC. Strategies to address persistent anterolateral rotatory laxity and ACL reconstruction failure are warranted due to the high rates of graft failure that we continue to see in young active individuals. There has been controversy over the ‘re-emergence’ of the ALL and associated anterolateral reconstructive procedures. It is, however, evident from this consensus that there is still considerable clinical research to be performed to determine the optimal scenarios for augmentation of a primary ACL reconstruction with an anterolateral procedure to improve outcomes for patients.

Acknowledgements The ALC Consensus Group would like to acknowledge the generous support from Smith and Nephew PLC to enable this meeting. ALC Consensus Group: Andrew Amis, UK; Charles Brown, UAE; Etienne Cavaignac, France; Steven Claes, Belgium; Matt Daggett, USA; David Dejour, France; Lars Engebretsen, Norway; Hua Feng, China; Braden Fleming, USA; Freddie Fu, USA; Andrew Geeslin, USA; Alan Getgood, Canada; Daniel Guenther, Germany; Camilo Partezani Helito, Brazil; Elmar Herbst, Germany; Eivind Inderhaug, Norway; Jon Karlsson, Sweden; Christoph Kittl, Germany; Ryosuke Kuroda, Japan; Robert LaPrade, USA; Philippe Landreau, Qatar; Tim Lording, Australia; Werner Mueller, Switzerland; Volker Musahl, USA; Phillippe Neyret, France; Frank Noyes, USA; Andrew Pearle, USA; Adnan Saithna, UK; Robert Smigielski, Poland; Bertrand Sonnery-Cottet, France; Tim Spalding, UK; Pieter Van Dyck, Belgium; Peter Verdonk, Belgium; Andy Williams, UK; Adrian Wilson, UK; and Stefano Zaffagnini, Italy.

Funding The ALC Consensus meeting was supported via an educational grant from Smith and Nephew PLC.

Compliance with ethical standards

Conflict of interest The authors declare that there is no Conflict of interest.

Ethical approval This article does not contain any studies with human participants or animals performed by any of the authors.

Informed consent For this type of study informed consent is not required.


References

- Albers M, Shaikh H, Herbst E, Onishi K, Nagai K, Musahl V et al (2018) The iliotibial band and anterolateral capsule have a combined attachment to the Segond fracture. *Knee Surg Sports Traumatol Arthrosc* 26:1305–1310
- Anderson AF, Snyder RB, Lipscomb AB Jr (2001) Anterior cruciate ligament reconstruction. A prospective randomized study of three surgical methods. *Am J Sports Med* 29:272–279
- Bell KM, Rahnama-Azar AA, Irrazaval S, Guenther D, Fu FH, Musahl V et al (2018) In situ force in the anterior cruciate ligament, the lateral collateral ligament, and the anterolateral capsule complex during a simulated pivot shift test. *J Orthop Res* 36:847–853
- Caterine S, Litchfield R, Johnson M, Chronik B, Getgood A (2015) A cadaveric study of the anterolateral ligament: re-introducing the lateral capsular ligament. *Knee Surg Sports Traumatol Arthrosc* 23:3186–3195
- Cavaignac E, Faruch M, Wytrykowski K, Constant O, Murgier J, Berard E et al (2017) Ultrasonographic evaluation of anterolateral ligament injuries: correlation with magnetic resonance imaging and pivot-shift testing. *Arthroscopy* 33:1384–1390
- Claes S, Luyckx T, Vereecke E, Bellemans J (2014) The Segond fracture: a bony injury of the anterolateral ligament of the knee. *Arthroscopy* 30:1475–1482
- Claes S, Vereecke E, Maes M, Victor J, Verdonk P, Bellemans J (2013) Anatomy of the anterolateral ligament of the knee. *J Anat* 223:321–328
- Corbo G, Norris M, Getgood A, Burkhart TA (2017) The infra-meniscal fibers of the anterolateral ligament are stronger and stiffer than the supra-meniscal fibers despite similar histological characteristics. *Knee Surg Sports Traumatol Arthrosc* 25:1078–1085
- Daggett M, Busch K, Sonnery-Cottet B (2016) Surgical dissection of the anterolateral ligament. *Arthrosc Tech* 5:e185–e188
- Devitt BM, Bell SW, Ardern CL, Hartwig T, Porter TJ, Feller JA et al (2017) The role of lateral extra-articular tenodesis in primary anterior cruciate ligament reconstruction: a systematic review with meta-analysis and best-evidence synthesis. *Orthop J Sports Med* 5:2325967117731767
- Devitt BM, Bouguennec N, Barfod KW, Porter T, Webster KE, Feller JA (2017) Combined anterior cruciate ligament reconstruction and lateral extra-articular tenodesis does not result in an increased rate of osteoarthritis: a systematic review and best evidence synthesis. *Knee Surg Sports Traumatol Arthrosc* 25:1149–1160
- Dodds AL, Halewood C, Gupte CM, Williams A, Amis AA (2014) The anterolateral ligament: anatomy, length changes and association with the Segond fracture. *Bone Jt J* 96-B:325–331
- Ferretti A, Monaco E, Fabbri M, Maestri B, De Carli A (2017) Prevalence and classification of injuries of anterolateral complex in acute anterior cruciate ligament tears. *Arthroscopy* 33:147–154
- Geeslin AG, Moatshe G, Chahla J, Kruckeberg BM, Muckenhirn KJ, Dornan GJ et al (2017) Anterolateral knee extra-articular stabilizers: a robotic study comparing anterolateral ligament reconstruction and modified Lemaire lateral extra-articular tenodesis. *Am J Sports Med*. <https://doi.org/10.1177/0363546517745268>
- Guenther D, Rahnama-Azar AA, Bell KM, Irrazaval S, Fu FH, Musahl V et al (2017) The anterolateral capsule of the knee behaves like a sheet of fibrous tissue. *Am J Sports Med* 45:849–855
- Helito CP, Demange MK, Bonadio MB, Tirico LE, Gobbi RG, Pecora JR et al (2013) Anatomy and histology of the knee anterolateral ligament. *Orthop J Sports Med* 1:2325967113513546
- Helito CP, Helito PV, Costa HP, Demange MK, Bordalo-Rodrigues M (2017) Assessment of the anterolateral ligament of the knee by magnetic resonance imaging in acute injuries of the anterior cruciate ligament. *Arthroscopy* 33:140–146
- Herbst E, Albers M, Burnham JM, Shaikh HS, Naendrup JH, Fu FH et al (2017) The anterolateral complex of the knee: a pictorial essay. *Knee Surg Sports Traumatol Arthrosc* 25:1009–1014
- Herbst E, Arilla FV, Guenther D, Yacuzzi C, Rahnama-Azar AA, Fu FH et al (2018) Lateral extra-articular tenodesis has no effect in

- knees with isolated anterior cruciate ligament injury. *Arthroscopy* 34:251–260
20. Hewison CE, Tran MN, Kaniki N, Remtulla A, Bryant D, Getgood AM (2015) Lateral extra-articular tenodesis reduces rotational laxity when combined with anterior cruciate ligament reconstruction: a systematic review of the literature. *Arthroscopy* 31:2022–2034
 21. Huser LE, Noyes FR, Jurgensmeier D, Levy MS (2017) Anterolateral ligament and iliotibial band control of rotational stability in the anterior cruciate ligament-intact knee: defined by tibiofemoral compartment translations and rotations. *Arthroscopy* 33:595–604
 22. Ibrahim SA, Shohdy EM, Marwan Y, Ramadan SA, Almisfer AK, Mohammad MW et al (2017) Anatomic reconstruction of the anterior cruciate ligament of the knee with or without reconstruction of the anterolateral ligament: a randomized clinical trial. *Am J Sports Med* 45:1558–1566
 23. Inderhaug E, Stephen JM, El-Daou H, Williams A, Amis AA (2017) The effects of anterolateral tenodesis on tibiofemoral contact pressures and kinematics. *Am J Sports Med* 45:3081–3088
 24. Inderhaug E, Stephen JM, Williams A, Amis AA (2017) Anterolateral tenodesis or anterolateral ligament complex reconstruction: effect of flexion angle at graft fixation when combined with ACL reconstruction. *Am J Sports Med* 45:3089–3097
 25. Inderhaug E, Stephen JM, Williams A, Amis AA (2017) Biomechanical comparison of anterolateral procedures combined with anterior cruciate ligament reconstruction. *Am J Sports Med* 45:347–354
 26. Kaplan EB (1958) The iliotibial tract; clinical and morphological significance. *J Bone Jt Surg Am* 40-A:817–832
 27. Kennedy MI, Claes S, Fuso FA, Williams BT, Goldsmith MT, Turnbull TL et al (2015) The anterolateral ligament: an anatomic, radiographic, and biomechanical analysis. *Am J Sports Med* 43:1606–1615
 28. Kittl C, El-Daou H, Athwal KK, Gupte CM, Weiler A, Williams A et al (2016) The role of the anterolateral structures and the ACL in controlling laxity of the intact and ACL-deficient knee. *Am J Sports Med* 44:345–354
 29. Kittl C, Halewood C, Stephen JM, Gupte CM, Weiler A, Williams A et al (2015) Length change patterns in the lateral extra-articular structures of the knee and related reconstructions. *Am J Sports Med* 43:354–362
 30. Klos B, Scholtes M, Konijnenberg S (2017) High prevalence of all complex Segond avulsion using ultrasound imaging. *Knee Surg Sports Traumatol Arthrosc* 25:1331–1338
 31. Lobenhoffer P, Posel P, Witt S, Piehler J, Wirth CJ (1987) Distal femoral fixation of the iliotibial tract. *Arch Orthop Trauma Surg* 106:285–290
 32. Lording T, Corbo G, Bryant D, Burkhart TA, Getgood A (2017) Rotational laxity control by the anterolateral ligament and the lateral meniscus is dependent on knee flexion angle: a cadaveric biomechanical study. *Clin Orthop Relat Res* 475:2401–2408
 33. Lubowitz JH, Provencher MT, Brand JC, Rossi MJ (2014) The knee anterolateral ligament. *Arthroscopy* 30:1385–1388
 34. Monaco E, Fabbri M, Mazza D, Daggett M, Redler A, Lanzetti RM et al (2018) The effect of sequential tearing of the anterior cruciate and anterolateral ligament on anterior translation and the pivot-shift phenomenon: a cadaveric study using navigation. *Arthroscopy* 34:1009–1014
 35. Muller W (1984) Functional anatomy and clinical findings of the knee joint. *Helv Chir Acta* 51:505–514
 36. Musahl V, Rahnama-Azar AA, Costello J, Arner JW, Fu FH, Hoshino Y et al (2016) The influence of meniscal and anterolateral capsular injury on knee laxity in patients with anterior cruciate ligament injuries. *Am J Sports Med* 44:3126–3131
 37. Musahl V, Rahnama-Azar AA, van Eck CF, Guenther D, Fu FH (2016) Anterolateral ligament of the knee, fact or fiction? *Knee Surg Sports Traumatol Arthrosc* 24:2–3
 38. Noyes FR, Huser LE, Jurgensmeier D, Walsh J, Levy MS (2017) Is an anterolateral ligament reconstruction required in ACL-reconstructed knees with associated injury to the anterolateral structures? A robotic analysis of rotational knee stability. *Am J Sports Med* 45:1018–1027
 39. Noyes FR, Huser LE, Levy MS (2017) Rotational knee instability in ACL-deficient knees: role of the anterolateral ligament and iliotibial band as defined by tibiofemoral compartment translations and rotations. *J Bone Jt Surg Am* 99:305–314
 40. O'Brien SJ, Warren RF, Wickiewicz TL, Rawlins BA, Allen AA, Panariello R et al (1991) The iliotibial band lateral sling procedure and its effect on the results of anterior cruciate ligament reconstruction. *Am J Sports Med* 19:21–24 (**discussion 24–25**)
 41. Pearl AJ, Bergfeld JA (1992) Extra-articular reconstruction in the anterior cruciate ligament deficient knee. *Am Orthop Soc Sports Med*
 42. Pernin J, Verdonk P, Si Selmi TA, Massin P, Neyret P (2010) Long-term follow-up of 24.5 years after intra-articular anterior cruciate ligament reconstruction with lateral extra-articular augmentation. *Am J Sports Med* 38:1094–1102
 43. Rasmussen MT, Nitri M, Williams BT, Moulton SG, Cruz RS, Dornan GJ et al (2016) An in vitro robotic assessment of the anterolateral ligament, Part 1: secondary role of the anterolateral ligament in the setting of an anterior cruciate ligament injury. *Am J Sports Med* 44:585–592
 44. Saiegh YA, Suero EM, Guenther D, Hawi N, Decker S, Krettek C et al (2017) Sectioning the anterolateral ligament did not increase tibiofemoral translation or rotation in an ACL-deficient cadaveric model. *Knee Surg Sports Traumatol Arthrosc* 25:1086–1092
 45. Schon JM, Moatshe G, Brady AW, Serra Cruz R, Chahla J, Dornan GJ et al (2016) Anatomic anterolateral ligament reconstruction of the knee leads to overconstraint at any fixation angle. *Am J Sports Med* 44:2546–2556
 46. Seebacher JR, Inglis AE, Marshall JL, Warren RF (1982) The structure of the posterolateral aspect of the knee. *J Bone Jt Surg Am* 64:536–541
 47. Segond P (1879) Recherches cliniques et experimentales sur les epanchements sanguins du genou par entorse. *Progres Medical*. <http://www.patrimoine.edilivre.com/>
 48. Shybut TB, Vega CE, Haddad J, Alexander JW, Gold JE, Noble PC et al (2015) Effect of lateral meniscal root tear on the stability of the anterior cruciate ligament-deficient knee. *Am J Sports Med* 43:905–911
 49. Smeets K, Slane J, Scheys L, Forsyth R, Claes S, Bellemans J (2017) The anterolateral ligament has similar biomechanical and histologic properties to the inferior glenohumeral ligament. *Arthroscopy* 33:1028–1035 (**e1021**)
 50. Song GY, Hong L, Zhang H, Zhang J, Li Y, Feng H (2016) Clinical outcomes of combined lateral extra-articular tenodesis and intra-articular anterior cruciate ligament reconstruction in addressing high-grade pivot-shift phenomenon. *Arthroscopy* 32:898–905
 51. Sonnery-Cottet B, Lutz C, Daggett M, Dalmay F, Freychet B, Niglis L et al (2016) The involvement of the anterolateral ligament in rotational control of the knee. *Am J Sports Med* 44:1209–1214
 52. Sonnery-Cottet B, Saithna A, Cavalier M, Kajetanek C, Temponi EF, Daggett M et al (2017) Anterolateral ligament reconstruction is associated with significantly reduced ACL graft rupture rates at a minimum follow-up of 2 years: a prospective comparative study of 502 patients from the SANTI study group. *Am J Sports Med* 45:1547–1557
 53. Sonnery-Cottet B, Thauinat M, Freychet B, Pupim BH, Murphy CG, Claes S (2015) Outcome of a combined anterior cruciate

- ligament and anterolateral ligament reconstruction technique with a minimum 2-year follow-up. *Am J Sports Med* 43:1598–1605
54. Spencer L, Burkhart TA, Tran MN, Rezansoff AJ, Deo S, Catherine S et al (2015) Biomechanical analysis of simulated clinical testing and reconstruction of the anterolateral ligament of the knee. *Am J Sports Med* 43:2189–2197
 55. Terry GC, Hughston JC, Norwood LA (1986) The anatomy of the iliopatellar band and iliotibial tract. *Am J Sports Med* 14:39–45
 56. Thaanat M, Clowez G, Saithna A, Cavalier M, Choudja E, Vieira TD et al (2017) Reoperation rates after combined anterior cruciate ligament and anterolateral ligament reconstruction: a series of 548 patients from the SANTI study group with a minimum follow-up of 2 years. *Am J Sports Med* 45:2569–2577
 57. Thein R, Boorman-Padgett J, Stone K, Wickiewicz TL, Imhauser CW, Pearle AD (2016) Biomechanical assessment of the anterolateral ligament of the knee: a secondary restraint in simulated tests of the pivot shift and of anterior stability. *J Bone Jt Surg Am* 98:937–943
 58. Vieira EL, Vieira EA, da Silva RT, Berlfein PA, Abdalla RJ, Cohen M (2007) An anatomic study of the iliotibial tract. *Arthroscopy* 23:269–274
 59. Vincent JP, Magnussen RA, Gezmez F, Uguen A, Jacobi M, Weppe F et al (2012) The anterolateral ligament of the human knee: an anatomic and histologic study. *Knee Surg Sports Traumatol Arthrosc* 20:147–152
 60. Webster KE, Feller JA (2016) Exploring the high reinjury rate in younger patients undergoing anterior cruciate ligament reconstruction. *Am J Sports Med* 44:2827–2832
 61. Zaffagnini S, Marcheggiani Muccioli GM, Grassi A, Roberti di Sarsina T, Raggi F, Signorelli C et al (2017) Over-the-top ACL reconstruction plus extra-articular lateral tenodesis with hamstring tendon grafts: prospective evaluation with 20-year minimum follow-up. *Am J Sports Med* 45:3233–3242
 62. Zens M, Niemeyer P, Ruhhammer J, Bernstein A, Woias P, Mayr HO et al (2015) Length changes of the anterolateral ligament during passive knee motion. *Am J Sports Med* 43:2545–2552

Affiliations

Alan Getgood¹  · Charles Brown² · Timothy Lording³ · Andrew Amis⁴ · Steven Claes⁵ · Andrew Geeslin⁶ · Volker Musahl⁷ on behalf of ALC Consensus Group

Charles Brown
charliebrownguestosa@yahoo.com

Timothy Lording
tlording@iinet.net.au

Andrew Amis
a.amis@imperial.ac.uk

Steven Claes
Steven@kreuzfeldverein.be

Andrew Geeslin
andrew.geeslin@gmail.com

Volker Musahl
vmusahl@gmail.com

¹ Fowler Kennedy Sport Medicine Clinic, University of Western Ontario, 3M Centre, London, ON N6A 3K7, Canada

² International Knee and Joint Centre, Abu Dhabi, UAE

³ Melbourne Orthopaedic Group, Melbourne, Australia

⁴ Imperial College London, London, UK

⁵ AZ Herentals, Herentals, Belgium

⁶ Western Michigan University, Kalamazoo, MI, USA

⁷ University of Pittsburgh Medical Centre, Pittsburgh, PA, USA